

# Letters to the Editor

Stroke welcomes Letters to the Editor and will publish them, if suitable, as space permits. They should not exceed 1000 words (excluding references) and may be subject to editing or abridgment. Please submit letters in duplicate, typed double-spaced. Include a fax number for the corresponding author and a completed copyright transfer agreement form (published in the January and July issues).

## Cerebral Venous Thrombosis and the G20210A Mutation of Factor II

To the Editor:

In addition to the article of Longstreth et al<sup>1</sup> recently published in *Stroke*, we describe 2 cases of stroke due to cerebral venous thrombosis with the G20210A mutation as only risk factor.

After sequencing of the gene for human prothrombin (factor II) by Degen and Davie<sup>2</sup> in 1987, a new mutation of prothrombin (G20210A) was described by Poort et al<sup>3</sup> in 1996. It is a common mutation of this factor associated with an increased risk of venous (and possible arterial) thrombosis, as stated by Martinelli et al.<sup>4</sup> The mutation can be detected by a polymerase chain reaction–restriction fragment length polymorphism (PCR-RFLP) method, as described by Poort.<sup>3</sup> Our laboratory uses this method.

Recently, we saw 2 patients with a definite diagnosis of cerebral venous thrombosis. No other known risk factor for cerebral venous thrombosis could be found. The finding of the abnormal mutation (G20210A) of factor II gene (both patients had a heterozygous state for the mutation) suggested this as etiology.

Patient 1 was a 42-year-old employee and moderate smoker. In his early thirties he had an arterial thrombectomy in a peripheral artery. In his family only his father had suffered a “stroke.” He was admitted to our hospital with a first epileptic seizure, focal in origin. There was a venous infarction in the right frontal lobe. MR angiography (including venous phase) showed a typical stop in the frontal superior sagittal sinus, with loss of draining veins. None of the other tests associated with venous hypercoagulability showed a hypercoagulable state (no activated protein C resistance, proteins C or S deficiency, detectable antinuclear factors, lupus anticoagulants, or antithrombin III). The G20210A mutation was found, showing a heterozygous genotype for this mutation in this patient.

Patient 2 was a 63-year-old farmer who was admitted to our hospital 3 days after being missed by his family. He didn't return home after market day and was disorientated in place, time, and person. A few days earlier, his family had found him to be a little distracted. CT and MRI showed a bithalamic venous infarction. On MR angiography and arteriography there was total obliteration of deep intracerebral venous structures. Anticoagulation was started. He remained with disinhibited frontal behavior. None of the classical risk factors of hypercoagulation were present. He did not smoke. By PCR-RFLP (as described above), he proved to be heterozygous for the G20210A mutation.

Besides being a well-known and relatively frequent risk factor for venous thrombosis in general, this mutation must be looked for in the less-frequent cerebral venous thrombosis patients. Testing for this mutation is important because people with this genotype should be strongly advised to avoid other risk factors, such as oral contraceptive use<sup>5</sup> and smoking.

Pieter Jan Simons, MD  
Geert Vanhooren, MD  
Stroke Unit  
Department of Neurology  
St Janshospitaal  
Bruges, Belgium

young women and two prothrombotic mutations: factor V Leiden and prothrombin gene variant (G20210A). *Stroke*. 1998;29:577–580.

2. Degen SJF, Davie EW. Nucleotide sequence of the gene for human prothrombin. *Biochemistry*. 1987;26:6165–6177.
3. Poort SR, Rosendaal FR, Reitsma PH, Bertina RM. A common genetic variation in the 3'-untranslated region of the prothrombin gene is associated with elevated plasma prothrombin levels and an increase in venous thrombosis. *Blood*. 1996;88:3698–3703.
4. Martinelli I, Sacchi E, Landi G, Taioli E, Duca F, Mannucci PM. High risk of cerebral-vein thrombosis in carriers of a prothrombin-gene mutation and in users of oral contraceptives. *N Engl J Med*. 1998;338:1793–1797.
5. Van Krimpen J, Leebeek FWG, Dippel DWJ, Gomez Garcia E. Prothrombin gene variant (G20210A) in a patient with cerebral venous sinus thrombosis. *Clin Neurol Neurosurg*. 1999;101:53–55.

## Response

Many thanks to Drs Simons and Vanhooren for sharing their interesting patients. Since the initial description by Bloem and colleagues<sup>1</sup> of a patient with sagittal sinus thrombosis and the prothrombin gene variant (G20210A), others have described similarly affected patients.<sup>2–6</sup> In addition to the prothrombin gene mutation, these patients often have other condition that promote thrombosis, such as use of oral contraceptives. We saw such a patient recently with the mutation and a well-recognized but unusual prothrombotic condition.

The patient was a 20-year-old man who developed headaches and deep-vein thrombosis in the right lower extremity following orthopedic surgery on his right knee. The headaches worsened, and he developed diplopia. He had a history of recurrent aphthous ulcers of the mouth but had otherwise been healthy and very athletic. On neurological examination, he had papilledema and a right sixth nerve palsy. His C-reactive protein was markedly elevated at 20.8 mg/dL (normal range being from 0 to 1.0 mg/dL). His venogram on cranial MRI showed a superior sagittal sinus thrombosis. During his hospitalization, he developed ulcers on his scrotum and thighs, from which bacterial and viral cultures were negative. He also demonstrated pathergy. Based on these observations, the dermatologists diagnosed Behçet's disease.<sup>7</sup> Although he was found to be negative for factor V Leiden, he was heterozygous for the prothrombin gene variant (G20210A). He improved with anticoagulation and pentoxifylline<sup>8</sup> but eventually required prednisone and colchicine to control recurrent skin lesions and fever.

Behçet's disease is known to be associated with cerebral venous thrombosis,<sup>9</sup> and factor V Leiden has been reported to increase the risk of venous thrombosis in patients with Behçet's disease.<sup>10</sup> We are not aware of previous patients with cerebral venous thrombosis, Behçet's disease, and the prothrombin gene variant. Given the combined prothrombotic effects of Behçet's disease and the prothrombin gene variant, the association is not unexpected.

W.T. Longstreth, Jr, MD, MPH  
Department of Neurology

Roy M. Colven, MD  
Department of Medicine  
Division of Dermatology  
University of Washington  
Harborview Medical Center  
Seattle, Washington

1. Longstreth WT Jr, Rosendaal FR, Siscovick DS, Vos HL, Schwartz SM, Psaty BM, Raghunathan TE, Koepsell TD, Reitsma PH. Risk of stroke in

1. Bloem BR, van Putten MJ, van der Meer FJ, van Hilten JJ, Bertina RM. Superior sagittal sinus thrombosis in a patient heterozygous for the novel 20210 A allele of the prothrombin gene. *Thromb Haemost*. 1998;79:235. Letter.
2. Longstreth WT Jr, Rosendaal FR, Siscovick DS, Vos HL, Schwartz SM, Psaty BM, Raghunathan TE, Koepsell TD, Reitsma PH. Risk of stroke in young women and two prothrombotic mutations: factor V Leiden and prothrombin gene variant (G20210A). *Stroke*. 1998;29:577–580.
3. Martinelli I, Sacchi E, Landi G, Taioli E, Duca F, Mannucci PM. High risk of cerebral-vein thrombosis in carriers of a prothrombin-gene mutation and in users of oral contraceptives. *N Engl J Med*. 1998;338:1793–1797.
4. Buisse V, Conard J, Brouzes C, Horellou MH, Ameri A, Bousser MG. Frequency of the 20210 G→A mutation in the 3'-untranslated region of the prothrombin gene in 35 cases of cerebral venous thrombosis. *Stroke*. 1998;29:1398–1400.
5. Reuner KH, Ruf A, Grau A, Rickmann H, Stolz E, Juttler E, Druschky KF, Patscheke H. Prothrombin gene G20210→A transition is a risk factor for cerebral venous thrombosis. *Stroke*. 1998;29:1765–1769.
6. Weih M, Mehraein S, Valdueza JM, Einhaupl KM, Vetter B, Kulozik AE. Coincidence of factor V Leiden mutation and a mutation in the prothrombin gene at position 20210 in a patient with puerperal cerebral venous thrombosis. *Stroke*. 1998;29:1739–1740.
7. International Study Group for Behçet's Disease. Criteria for diagnosis of Behçet's disease. *Lancet*. 1990;335:1078–1080.
8. Yasui K, Ohta K, Kobayashi M, Aizawa T, Komiya A. Successful treatment of Behçet disease with pentoxifylline. *Ann Intern Med*. 1996;124:891–893.
9. Wechsler B, Vidailhet M, Piette JC, Bousser MG, Dell Isola B, Blety O, Godeau P. Cerebral venous thrombosis in Behçet's disease: clinical study and long-term follow-up of 25 cases. *Neurology*. 1992;42:614–618.
10. Gul A, Ozbek U, Ozturk C, Inanc M, Konice M, Ozcelik T. Coagulation factor V gene mutation increases the risk of venous thrombosis in Behçet's disease. *Br J Rheumatol*. 1996;35:1178–1180.

## Asymptomatic Embolization Predicts Stroke and TIA Risk in Patients With Carotid Artery Stenosis

To the Editor:

It was very interesting to read in *Stroke* the article of Molloy et al,<sup>1</sup> as well as those of other investigators, concerning embolic signals (ES).<sup>2,3</sup> Since we believe that the use of transcranial Doppler (TCD) will contribute to the stratification of the high-risk patients who are candidates for sustaining a stroke, we would like to first congratulate the authors and to add certain observations and knowledge that might prove to be useful in such a future program.

I would like to enlarge upon the following points. (1) The investigation with TCD of patients depicting embolic signals (ES) of 60-minute duration has given an interesting outcome. The results may be more beneficial if the evolution of the method will finally permit its application on a 24-hour basis, similar to the Holter method used in cardiology. (2) The evaluation of the patients under everyday working conditions (hypertension period) might add profitable informative data. (3) Not only the quality but also the quantity of ES might be related to the frequency and gravity of the ensuing cerebral episode. (4) The placing of probes concomitantly on the thoracic wall and along the neck area will also signal the focus of origin of emboli (heart, aortic arch, carotid). (5) The intraoperative application of the method with preoperative and postoperative mapping with MRI of the brain will also proffer an answer for the value of various other technique at the aortic arch and its branches, relative to the presence of ES.

We would like to remark that the heart, as an embologenic focus, in the beginning of the study does not exclude, for example, 774 days later an ES of cardiac origin, because the cardiac cause might have ensued during the investigation.

A more sophisticated development of the method and its application in the form of a large multicenter study would render

it a remarkable method that might alter the refined and current indications for surgery and, moreover, the prognosis for these patients.

**P.B. Dimakakos**  
**B. Arapoglou**  
 Medical School  
 University of Athens  
 Areteion Hospital  
 Athens, Greece

1. Molloy J, Markus HS. Asymptomatic embolization predicts stroke and TIA risk in patients with carotid artery stenosis. *Stroke*. 1999;30:1440–1443.
2. Vacton L, Larrue V, Pavy Le Traon A, Massabau P, Geraud G. Micro-embolic signals and risk of early recurrence in patients with stroke or transient ischemic attack. *Stroke*. 1998;29:2125–2128.
3. Furui E, Hanzawa K, Ohzeki H, Nakajima T, Fukura N, Takamori M. "Tail sign" associated with microembolic signals. *Stroke*. 1999;30:863–866.

### Response

I thank Drs Dimakakos and Arapoglou for their comments. I agree that TCD detection in cerebral emboli is an exciting technique to stratify risk in patients with cardiovascular disease. Studies to date have provided most evidence for the clinical significance of Doppler embolic signals in patients with carotid artery stenosis, as described in our article and in previous studies. A number of previous studies have looked at patients with cardiogenic sources of emboli. The frequency of embolic signals in patients with atrial fibrillation appears to be lower than that found in carotid stenosis, and we were unable to find any association between the presence of embolic signals in patients with atrial fibrillation and clinical marks of increased risk.<sup>1</sup> More studies are required in this area. There has been relatively little work studying embolization in patients with aortic arch atheroma although current studies are underway. It certainly is possible to localize the source of embolization in patients by recording from multiple sites along the arterial system. We have performed such studies in patients with acute stroke and have localized the embolic source to the carotid bifurcation in individual patients.<sup>2</sup> However, such studies can be technically difficult. It is relatively easy to record for prolonged periods of time from the middle cerebral artery, as good probe fixation can be achieved using a head band. However, maintaining probe position on the common carotid artery is more difficult, because the position of the vessel may vary during swallowing and other normal activities. It is possible with improved technology that some of these difficulties may be overcome.

The prospective studies to date, including our own, have not been sufficiently large to determine whether there are particular thresholds or frequencies per hour of embolic signals that confer increased risk. Although our study and those of Valton et al<sup>3</sup> and Siebler et al<sup>4</sup> have shown that asymptomatic embolization predicts stroke risk in patients with large-artery disease, the confidence intervals are wide. For these reasons we are now carrying out a much larger international multicenter study to determine the predictive value of Doppler embolic signals in patients with asymptomatic carotid stenosis. This study, which will recruit 600 patients, is supported by the British Heart Foundation. If any centers are interested in taking part, they are encouraged to contact me at the address below.

**Prof Hugh Markus, DM**  
 Clinical Neuroscience  
 St George's Hospital Medical School  
 Cranmer Terrace  
 London SW17 ORE, UK  
 Telephone: 44-0181-672-9944/E-mail h.markus@sghms.ac.uk

1. Cullinane M, Wainwright R, Brown A, Monaghan M, Markus HS. Asymptomatic embolization in subjects with atrial fibrillation not taking anticoagulants: a prospective study. *Stroke*. 1998;29:1810–1815.
2. Kaposzta Z, Young E, Bath, PMW, Markus HS. The clinical application of asymptomatic embolic signal detection in acute stroke: a prospective study. *Stroke*. 1999;30:1814–1818.
3. Valton L, Larrue V, Le Traon AP, Massabuau P, Gerard G. Microembolic signals and risk of early recurrence in patients with stroke or transient ischemic attack. *Stroke*. 1998;29:2125–2128.
4. Siebler M, Nachtmann A, Sitzer M, Rose G, Kleinschmidt A, Rademacher J, Steinmetz H. Cerebral microembolism and the risk of ischaemia in asymptomatic high-grade internal carotid artery ischemia. *Stroke*. 1995; 26:2184–2186.

### Carotid Stenosis Determines Impairment of Ipsilateral Dexterity in Stroke

To the Editor:

I read with interest the article by Sunderland et al<sup>1</sup> in the May issue of *Stroke*. This study demonstrated that within 1 month of an infarct involving the parietal and/or posterior frontal lobe, the majority of left hemisphere patients and a smaller proportion of right hemisphere patients have impaired dexterity of the ipsilateral hand. This result was in agreement with prior studies.<sup>2</sup> They suggested that ipsilateral sensorimotor losses may contribute to these impairments, but the

major factor appeared to be the presence of cognitive deficits, and the nature of these deficits varied with side of brain damage.

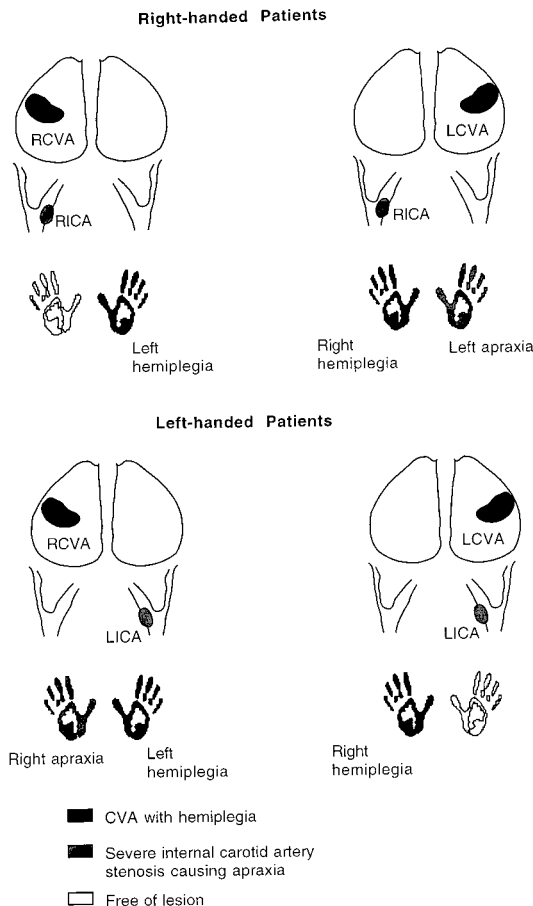
A review of the results in light of prior work in our laboratory reveals a rather simpler interaction of handedness, carotid plaque lesion, and apraxia. Since Fisher's first description of the relationship between stroke risk and extracranial carotid stenosis, several reports have shown that this risk increases with severity of the carotid lesion.<sup>3</sup> The relationship between handedness and severity of carotid stenosis has been demonstrated.<sup>4</sup> In right-handed persons, the size of the plaque in the right carotid system was greater than in the left ( $P=0.01$ ). In left-handed persons, there was a tendency for left carotid plaque size to be greater than that of the right. The odds of greater ipsilateral carotid plaque was 9 times, after controlling for the confounding variables.<sup>4</sup> In view of these findings, I hereby propose a model that will explain the results of the present study.<sup>1</sup> In right-handed patients with right cerebrovascular accidents (RCVA), left hemiplegia will result (see Figure, top panel). This maybe associated with the greater right internal carotid artery (RICA) plaque stenosis. No apraxia is expected on the ipsilateral right hand. This group comprised 13 patients in the study by Sunderland et al.<sup>1</sup> Conversely, in right-handed patients with left cerebrovascular accident (LCVA) (probably due to thromboembolus), right hemiplegia developed. However, because the RICA plaque is of greater severity, left apraxia developed ipsilateral to LCVA. This group comprised 15 patients in the study under discussion.<sup>1</sup> In left-handed patients (Figure, bottom) with RCVA, left hemiplegia was present. Because the left internal carotid artery (LICA) plaque lesion is of greater severity, right apraxia developed ipsilateral to RCVA. This group comprised 2 patients in the study.<sup>1</sup> Conversely, in left-handed patients with LCVA, no apraxia is expected ipsilateral to LCVA. This group was not studied.

The model here described as "carotid plaque apraxia" therefore postulates that ipsilateral apraxia arises mainly if CVA occurs in the hemisphere contralateral to handedness, as a result of significant carotid plaque lesions. This is of immense clinical relevance, because it will help to identify those patients who will require further investigation for carotid artery disease for prevention of a second stroke on the now-ipsilateral side.

Unfortunately, the authors did not present data on the severity of left and right carotid lesions in their sample population to allow further assessment of this postulate. I hope that extracting such data from their database may be possible and will be reported in a future publication with larger sample size.

Philip C. Njemanze, MD

Noninvasive Neurocybernetic Flow Laboratory  
International Institutes of Advanced Research and Training  
Chidicon Medical Center  
Owerri, Nigeria



Schematic representation of the relationship between lesion location and handedness. In right-handed patients with RCVA (■) and stenotic RICA plaque (◻), left hemiplegia (■), without ipsilateral apraxia (□). In those with LCVA (■) and right stenotic RICA plaque (◻), right hemiplegia (■) and left apraxia (◻) correspondingly develop. In left-handed patients with RCVA (■), left hemiplegia (■) and right apraxia (◻) correspondingly develop. In those with LCVA (■), only right hemiplegia develops without ipsilateral apraxia (□).

1. Sunderland A, Bowers MP, Sluman S-M, Wilcock DJ, Ardron ME. Impaired dexterity of the ipsilateral hand after stroke and the relationship to cognitive deficit. *Stroke*. 1999;30:949–955.
2. Spaulding SJ, McPherson JJ, Strachota E, Kuphal M, Ramponi M. Jebsen hand function test: performance of the uninvolved hand in hemiplegia and right-handed, right and left hemiplegic persons. *Arch Phys Med Rehabil*. 1988;69:419–422.
3. Fisher CM. Occlusion of the internal carotid artery. *Arch Neurol Psychiatry*. 1951;65:346–377.
4. Njemanze PC. Handedness and carotid plaque lesion. *Stroke*. 1992;23: 1679–1680.

### Response

I thank Dr Njemanze for his interest in our article, and I would like to respond on behalf of my colleagues.

An absolutely crucial aspect of our data concerned the distinctive pattern of ipsilateral impairment after left versus right hemisphere stroke. Had we simply found that ipsilateral dexterity was poorer after left hemisphere damage, this could conceivably have arisen from more frequent compromised function of the

supposedly intact right hemisphere. In fact, we found that left-hemisphere damage was associated with ipsilateral slowing and postural errors, whereas right-hemisphere damage was associated with visuospatial errors. These patterns of impairment would not be predicted from Dr Njemanze's simple model, whereas they are exactly what one would predict from lateralization of cognitive function.<sup>1</sup> The model we proposed was therefore that impaired ipsilateral dexterity reflects deficits in cognitive processing within the damaged hemisphere. These will impair performance with either hand, but this tends to be overshadowed by paresis on contralateral side.

To answer the specific points raised, unfortunately there is no detailed data on carotid lesions for the patients in the study. However, I have checked Dr Njemanze's suggestion that left-handed patients with RCVA should show "right apraxia." There were 2 such patients in the study. Neither showed any sign of ideomotor apraxia on action imitation, with perfect performance in both cases. One of them showed visual neglect on the cancellation test, and his errors on dexterity tests reflected this (eg, failing initially to pick up objects to his left). This is consistent with our proposal that the pattern of ipsilateral dexterity impairment reflects cognitive deficit.

**Alan Sunderland, PhD**  
 Division of Stroke Medicine  
 University of Nottingham  
 Nottingham, United Kingdom

1. Kolb B, Whishaw IQ. *Fundamentals of Human Neuropsychology*. 4th ed. New York, NY: WH Freeman; 1996.

## Induced Elevation of Blood Pressure in the Acute Phase of Ischemic Stroke in Humans

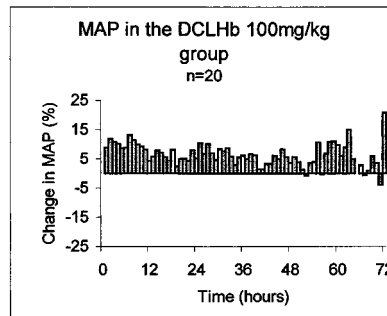
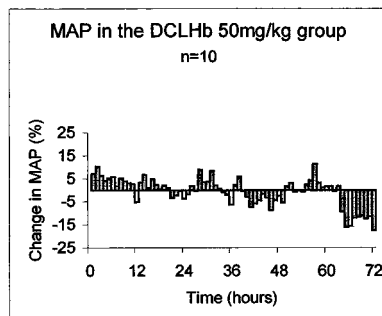
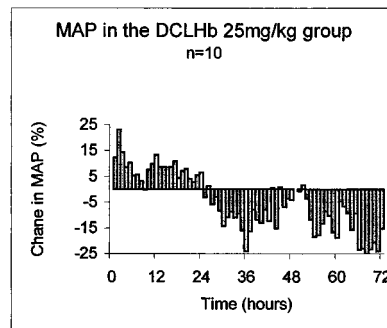
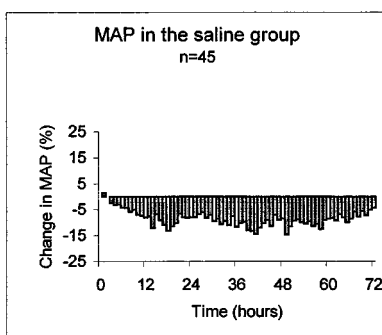
To the Editor:

Blood pressure is often elevated in the acute phase of stroke. Possible reasons are previous hypertension, a pathophysiological response to ensure perfusion in the ischemic penumbra, or a reaction to the stress of hospitalization. The course of blood

pressure following an acute stroke has been extensively studied and shows a spontaneous decline during the first week.<sup>1-5</sup>

Decreasing the blood pressure in the acute phase of stroke can have a deleterious effect on outcome.<sup>6,7</sup> The consensus is not to treat high blood pressure during the first week, except for a consistently elevated systolic blood pressure >250 mm Hg or diastolic blood pressure >140 mm Hg.<sup>8,9</sup> The safety and efficacy of increasing blood pressure is completely unknown. The rationale for this therapy is that it may help to restore the blood flow to the ischemic area of which the perfusion is passively dependent on the systemic blood pressure because of the loss of local autoregulation, or it may induce dilatation of the leptomeningeal collateral circulation in case of an embolic occlusion. Early reports in humans<sup>10,11</sup> and recent experimental work<sup>12,13</sup> have shown a beneficial effect on outcome of treatment with induced hypertension.<sup>14,15</sup>

In animal stroke models, diaspirin cross-linked hemoglobin (DCLHb), a purified cell-free human oxygen-carrying hemoglobin solution, produced both an increase in blood pressure and tissue perfusion and a significant reduction in the extent of brain injury.<sup>16,17</sup> We recently performed a safety study of DCLHb in patients with acute ischemic stroke, which to our knowledge is the first to elevate blood pressure in a randomized controlled fashion.<sup>18</sup> DCLHb in a dose-increasing fashion (25, 50, and 100 mg/kg; n=10, n=10, and n=20, respectively) or placebo (n=45) was infused intravenously every 6 hours for 72 hours in patients with an acute ischemic stroke in the anterior circulation, within 18 hours of onset of symptoms, in the setting of a randomized, controlled, single-blind trial. During the first 80 hours, blood pressure and heart rate were measured at 15-minute intervals with an automatic, oscillometric blood pressure device and 4 times daily thereafter. A CT scan was performed on admission and after 2 weeks and a MRI scan around day 7. Safety was further monitored by repeated physical and neurological examinations, and patients were checked for adverse events on a daily basis while admitted and again at 3 months. Outcome at 3 months was measured by means of the Modified Rankin scale. Because a similar protocol was followed for all patients, the data of the 3 placebo groups were combined.



Relative changes in mean arterial pressure (MAP) in relation to baseline values, in percentage of baseline values.

### Blood Pressure (mm Hg) During the Treatment Period of 72 Hours

	Saline	DCLHb		
		25 mg/kg	50 mg/kg	100 mg/kg
n	45	10	10	20
Mean MAP±SD	99±11	102±9	112±10*	117±13*#
95% CI for MAP	95–102	96–108	105–120	111–123
Mean SBP±SD	141±17	146±13	163±21*	166±20*#
95% CI for SBP	136–146	137–155	148–178	157–176
Mean DBP±SD	78±10	80±9	87±7	92±11
95% CI for DBP	75–81	74–86	81–92	87–97
Mean HR±SD	73±13	79±17	74±14	74±13
95% CI for HR	69–77	67–92	64–84	68–80

MAP indicates mean arterial pressure; SBP, systolic blood pressure; DBP, diastolic blood pressure; and HR, heart rate.

\*Significant change from saline.

#Significant change from DCLHb 25 mg/kg.

We present the data on blood pressure and have specifically focused on the commonly feared complications of this therapy: hypertensive encephalopathy, hemorrhagic transformation, brain edema, myocardial infarction, and congestive heart failure.<sup>19</sup>

Blood pressure was elevated (>150/90 mm Hg) in 64% of the patients on admission, whereas 45% were known to have hypertension.

In the control group the blood pressure on admission was 155±20/85±12 mm Hg. The systolic and diastolic pressures were significantly lower at 24 hours: 140±25 mm Hg ( $P=0.01$ ) and 78±16 mm Hg ( $P=0.01$ ) and did not fall further during the 2 weeks of observation. There were no significant changes in heart rate.

After the first infusion, DCLHb produced a rapid rise in blood pressure, which depended more on an elevation of the systolic than the diastolic pressure. It reached a maximum within 2 hours after the first infusion. For the treatment group as a whole ( $n=40$ ), the systolic pressure increased from 158±23 mm Hg at baseline to 172±27 mm Hg versus 156±24 mm Hg in controls ( $P=0.005$ ). The diastolic pressure increased from 83±14 mm Hg to 94±15 mm Hg versus 84±17 mm Hg in controls ( $P=0.008$ ). The magnitude of the increases caused by the different doses was similar, but the duration of the pressor effect was dose dependent despite the repeated infusions (Figure).

In the patients treated with DCLHb ( $n=40$ ), blood pressure on admission (158±23/83±14 mm Hg) did not fall during the treatment period of 72 hours. By day 7 the blood pressure had significantly decreased to 130±7/78±9 mm Hg ( $P=0.05$ ). The mean arterial pressure during the treatment phase of 72 hours was dose dependently higher in the DCLHb-treated groups. Heart rates in the 4 groups were similar (Table).

Cerebral edema/coning occurred in 4 patients treated with DCLHb versus 0 in the placebo group ( $P=0.05$ ), but multiple regression analysis showed that this was related to a misbalance in severe stroke at baseline rather than to treatment with DCLHb.<sup>18</sup> Hypertension that needed pharmacological intervention (>220/135 mm Hg for 1 hour) occurred in 4 patients treated with DCLHb versus 5 in the saline group. Hemorrhagic transformation occurred in 2 patients treated with DCLHb versus 6 in the saline group ( $P=0.17$ ). There were no significant differences in the prevalence of myocardial ischemia or cardiac failure. Hypertensive encephalopathy did not occur at all.

To conclude, DCLHb caused a pressor effect that delayed the fall in blood pressure which normally occurs in stroke patients and which was also seen in our control group. The induction of

hypertension was performed without complications such as hemorrhagic transformation, edema, or hypertensive encephalopathy.

It is impossible to draw conclusions regarding the clinical effect on outcome, since DCLHb is an agent with more effects than only hypertension. In a previous article,<sup>20</sup> we reported a dose-dependent increase in endothelin-1 (ET-1) levels in our patients, and in the above-mentioned article the worse outcome in the treatment group seemed to be independently related to the use of DCLHb.<sup>18</sup> Also, a North American and European study in trauma patients was recently prematurely terminated because of higher mortality in the treatment group.<sup>21</sup>

Further studies should therefore try to evaluate other methods of induced hypertension and explore their clinical efficacy.

This work was supported by the Baxter HealthCare Corporation, Round Lake, Ill, and the Stichting Neurovasculair Onderzoek, Rotterdam, the Netherlands.

#### On behalf of the DCLHb in Acute Stroke Study Investigators\*

Ritu Saxena, MD

Annemarie D. Wijnhoud, MD

Peter J. Koudstaal, MD

Department of Neurology

Anton H. van den Meiracker, MD

Department of Internal Medicine

University Hospital Dijkzigt

Rotterdam, the Netherlands

\*Rotterdam: Ritu Saxena, MD, clinical coordinator; Anne-Marie D. Wijnhoud, MD, investigator; Prof Peter J. Koudstaal, MD, principal investigator. Leuven: Prof Herwig Carton, MD, investigator. Heidelberg: Werner Hacke, MD, investigator. Helsinki: Markku Kaste, MD, investigator. Advisory Board: Department of Internal Medicine, Rotterdam: Prof Arie J. Man in't Veld, MD; Anton H. van den Meiracker, MD; Frans Boomsma, MSc. Baxter HealthCare Corporation: Robert J. Przybelski, MD; Kathleen N. Stern, PhD.

- Harper G, Fotherby MD, Panayiotou BJ, Castleden CM, Potter JF. The changes in blood pressure after acute stroke: abolishing the "white coat effect" with 24-h ambulatory monitoring. *J Intern Med.* 1994;235:343–346.
- Carlberg B, Asplund K, Hagg E. Factors influencing admission blood pressure levels in patients with acute stroke. *Stroke.* 1991;22:527–530.
- Carlberg, B., Asplund, K, Hagg, E. Course of blood pressure in different subsets of patients after acute stroke. *Stroke.* 1991;1:281–287.
- Wallace JD, Levy LL. Blood pressure after stroke. *JAMA.* 1981;246:2177–2180.
- Britton M, Carlsson A, de Faire U. Blood pressure course in patients with acute stroke and matched controls. *Stroke.* 1986;17:861–864.
- Kaste M, Fogelholm R, Eriola T, Palomaki H, Murros K, Rissanen A, Sarna S. A randomized, double-blind, placebo-controlled trial of nimodipine in acute ischemic hemispheric stroke. *Stroke.* 1994;25:1348–1353.
- Wahlgren N, MacMahon D, Keyser JD, Indredavik B, Ryman T. Intravenous nimodipine West European stroke trial (INWEST): nimodipine in the treatment of acute ischaemic stroke. *Crit Care Med.* 1994;4:204–210.
- Yatsu FM, Zivin J. Hypertension in acute ischemic strokes: not to treat. *Arch Neurol.* 1985;42:999–1000.
- Spence JD, Del Maestro RF. Hypertension in acute ischemic strokes. *Treat Arch Neurol.* 1985;42:1000–1002.
- Wise GR. Vasopressor-drug therapy for complications of cerebral arteriography. *N Engl J Med.* 1970;282:610–612.
- Wise G, Sutter R, Burkholder J. The treatment of brain ischemia with vasopressor drugs. *Stroke.* 1972;3:135–140.
- Patel PM, Drummond JC, Cole DJ, Giabella R, Steinauer J. Delayed institution of hypertension during focal cerebral ischemia: effect on brain edema. *Acta Neuropathol (Berl).* 1991;81:339–344.
- Patel PM, Drummond JC, Cole DJ. Induced hypertension during restoration of flow after temporary middle cerebral artery occlusion in the rat: effect on neuronal injury and edema. *Surg Neurol.* 1991;36:195–201.
- Rordorf G, Cramer SC, Efrid JT, Schwamm LH, Buonanno F, Koroshetz WJ. Pharmacological elevation of blood pressure in acute stroke: clinical effects and safety. *Stroke.* 1997;28:2133–2138.

15. Duke BJ, Breeze RE, Rubenstein D, Tranmer BI, Kindt GW. Induced hypervolemia and inotropic support for acute cerebral arterial insufficiency: an underused therapy. *Surg Neurol.* 1998;49:51–54.
16. Bowes MP, Burhop KE, Zivin JA. Diaspirin cross-linked hemoglobin improves neurological outcome following reversible but not irreversible CNS ischemia in rabbits. *Stroke.* 1994;25:2253–2257.
17. Cole DJ, Nary JC, Drummond JC, Patel PM, Jacobsen WK. Alpha-alpha diaspirin cross-linked hemoglobin, nitric oxide, and cerebral ischemic injury in rats. *Artif Cells Blood Substit Immobil Biotechnol.* 1997;25:141–152.
18. Saxena R, Wijnhoud AD, Carton H, Hacke W, Kaste M, Przybelski RJ, Koudstaal PJ. Controlled safety study of a hemoglobin-based oxygen carrier, DCLHb, in acute ischemic stroke. *Stroke.* 1999;30:993–996.
19. Kassell NF, Peerless SJ, Durward QJ, Beck DW, Drake CG, Adams HP. Treatment of ischemic deficits from vasospasm with intravascular volume expansion and induced arterial hypertension. *Neurosurgery.* 1982;11:337–343.
20. Saxena R, Wijnhoud AD, Man in't Veld AJ, van den Meiracker AH, Boomsma F, Przybelski RJ, Koudstaal PJ. Effect of diaspirin cross-linked hemoglobin on endothelin-1 and blood pressure in acute ischemic stroke in man. *J Hypertens.* 1998;16:1459–1465.
21. Baxter Healthcare Corporation. Baxter suspends European Trauma trial for its hemoglobin therapeutic. Available at: <http://www.baxter.com/utilities/news/build.html?releases/1999/07-12cvg.html>. Accessed June 2, 1998.